

BEHAVIOR OF THE CARDIOVASCULAR DISEASES IN WOMEN

Ma. Amparo Pineda T¹, Alberto Ortega R¹, Joel Álvarez P.

¹ Nuclear Medicine Department, ² Cardiology Hospital, National Medical Center, IMSS; Av. Cuauhtémoc 330, México D.F. E-mail: pamparo27@yahoo.com.mx

Background

Coronary artery disease (CAD) remains the leading cause of death in Mexico and Western world. Symptoms in women are more subtle. Women usually feel general tiredness and lack of energy, in contrast to men having chest pain. This implies that women do not receive a timely and early diagnosis. According to the National Health Information System, 20 of 100 Mexican women die of cardiovascular disease, 68.5% of Mexicans have problems of obesity, overweight, diabetes, high blood pressure, conditions that increase the risk of CAD. SPECT myocardial perfusion scintigraphy (MPS) is currently appropriate for diagnosis, risk assessment, stratification, myocardial viability, evaluation of left ventricular function. The Objective of this investigation is to show that SPECT MPS is a noninvasive diagnostic test that identify women with increased CAD risk.

Method

A 60 years old female patient with diabetes, high blood pressure and overweight was referred for a cardiac scan, for suspicion of ischemia. Her symptoms were general tiredness, lack of energy and occasionally light chest pain. A SPECT-gated myocardial perfusion test was done. The images were acquired with a gamma camera after the injection of 10 mCi (pharmacologic stress) and 20 mCi (Rest) of 99mTc-Tetrofosmin. Images were reconstructed using Emory toolbox.

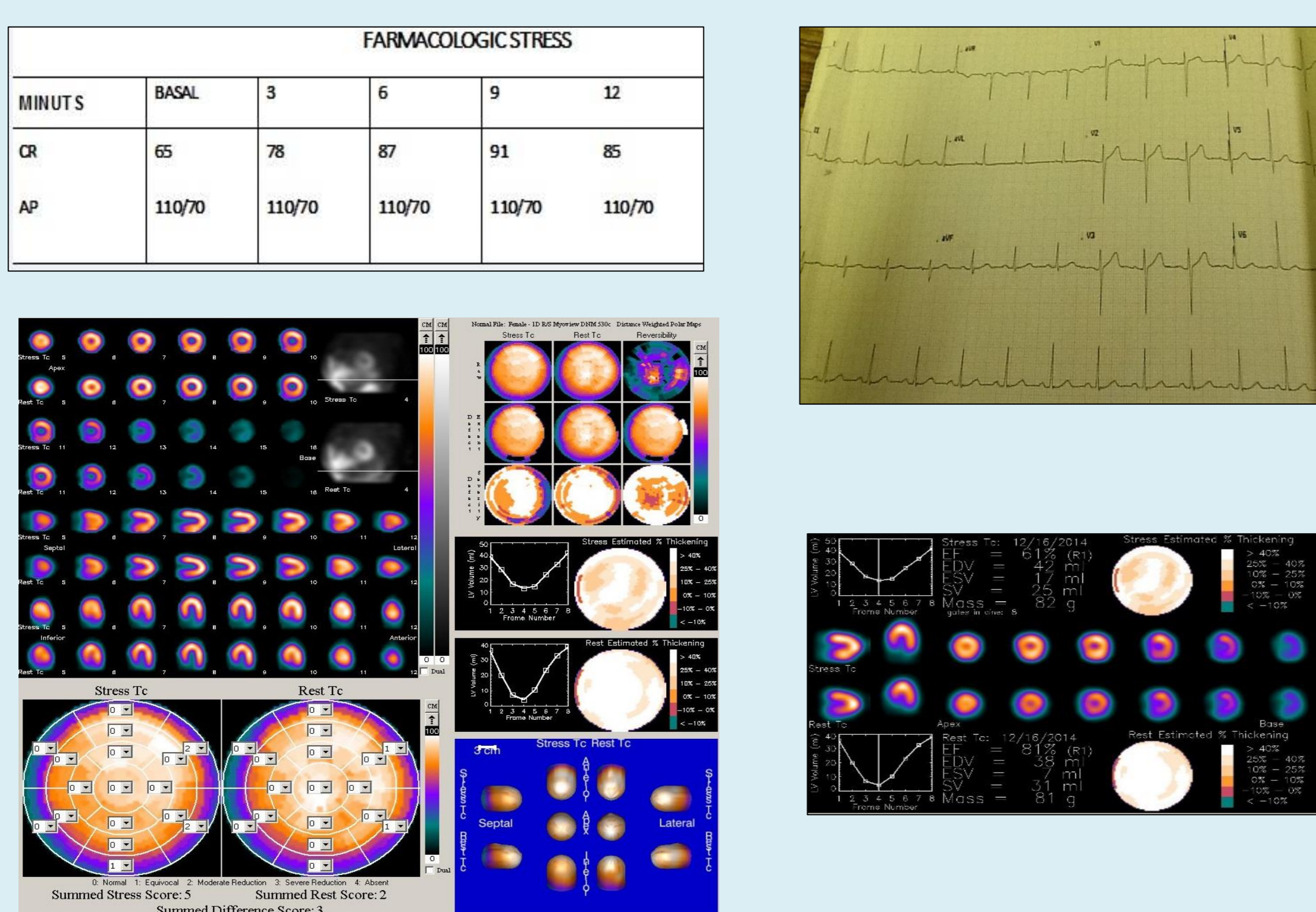


FIGURE 1

Results

The dipyridamole test showed no changes in the electrocardiogram and the images scintigraphic showed light hypoperfusion septal and inferior walls, and a small left ventricular chamber size with thickened walls (Fig.1). The ejection fraction was $> 65\%$, without mobility alterations.

Angiographic image (Fig.2) showed bifurcated main trunk, Left descending artery with diffuse atherosclerotic disease and obstruction between 50 % and 90 %, Circumflex artery is dominant with atherosclerotic, obstructive lesions of 75% in proximal medial and distal segments; Right coronary artery is dominant, with several significant atherosclerotic lesions. that means the Angiography showed significant diffuse coronary stenosis in the three vessels.

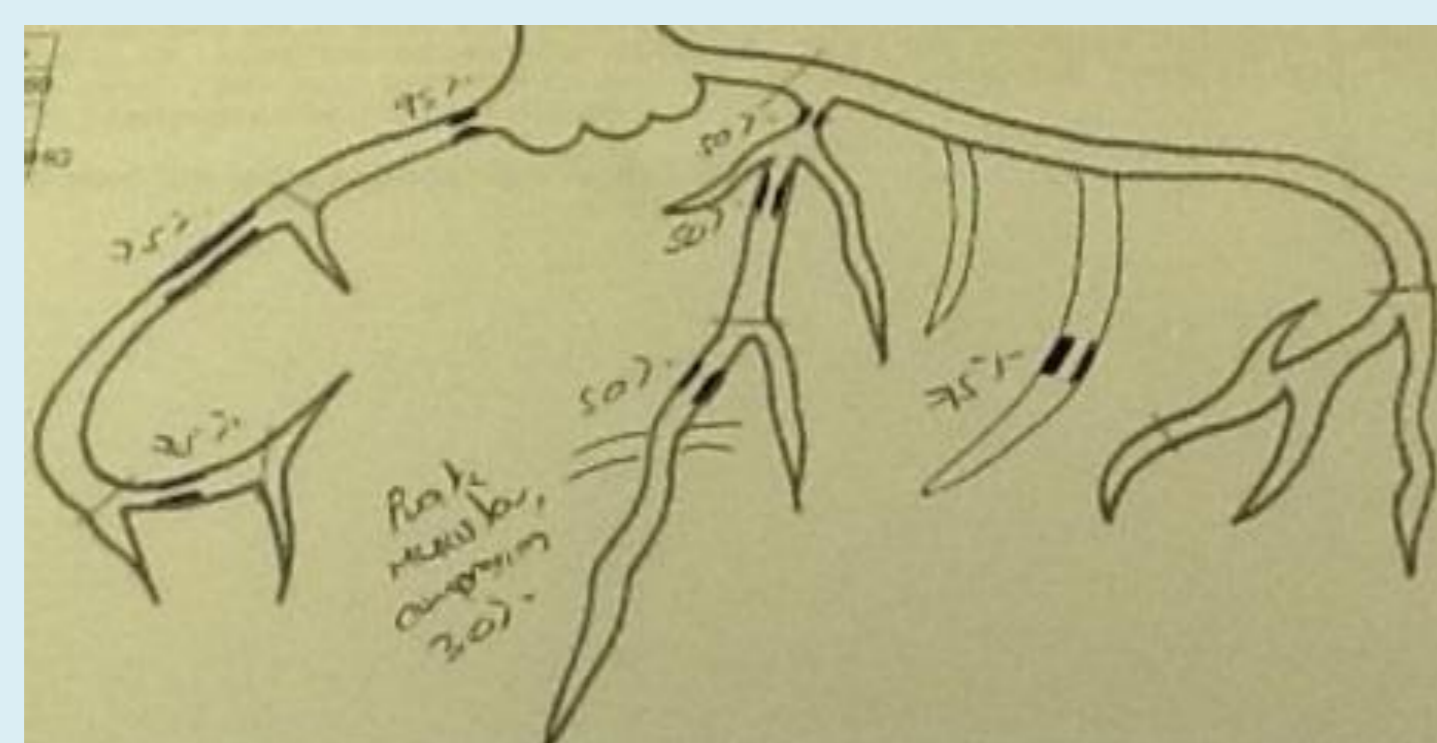
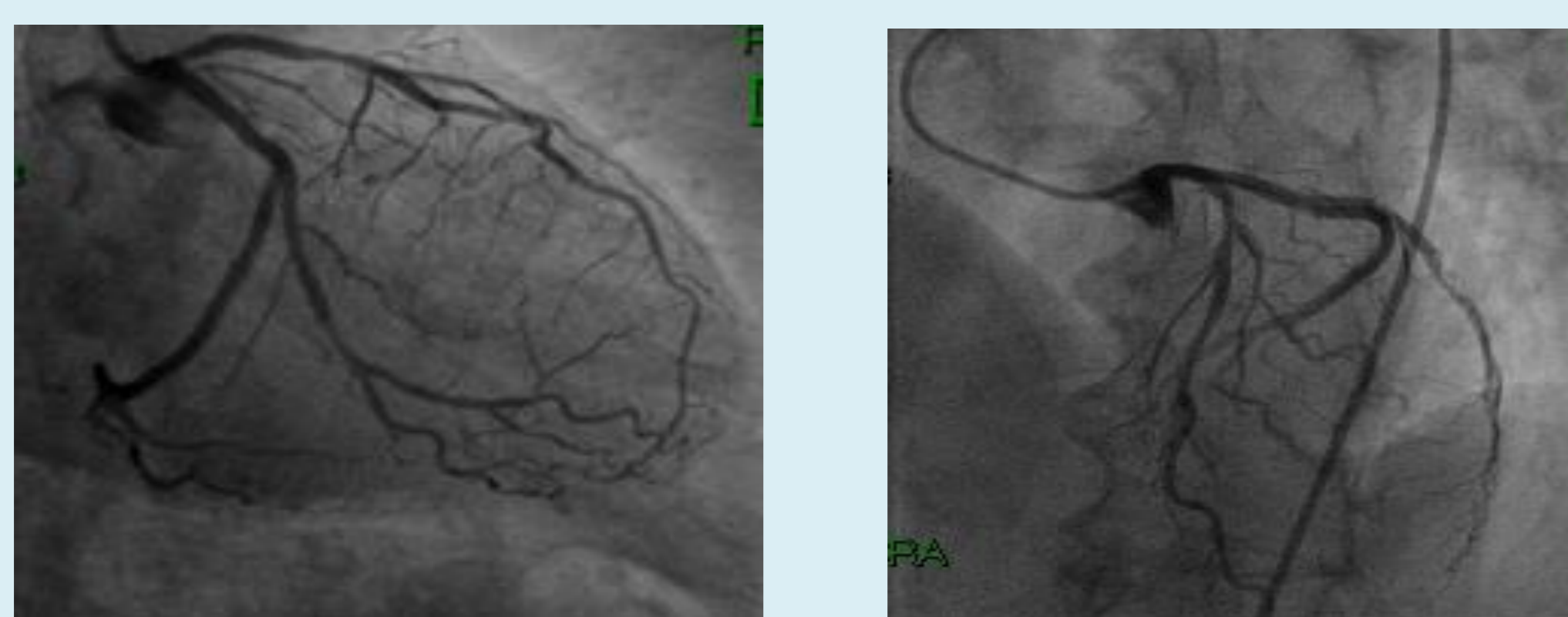


Figure 2. Angiography image

Conclusion

Coronary artery diseases are a confusing topic in Women suffering CAD because the symptoms are more subtle and they constitute a high-risk group that potentially means a diagnostic and therapeutic challenge.

Cardiac SPECT MPS is a noninvasive diagnostic and prognostic test that identify women with high CAD risk and establish timely and early the therapeutic interventions.

Bibliography.

1. Stock EO, Redberg R, Cardiovascular disease in women. *Curr Probl Cardiol*. 2012 Nov; 37(11):450-526.
2. Jennifer H. Mieres, MD, et al. Role of Noninvasive Testing in the Clinical Evaluation of Women With Suspected Coronary Artery Disease. *Circulación*. 2005; 111:682-696.
3. Udo Sechtem, et al. Non-invasive imaging in acute chest pain syndromes. *European Heart Journal – Cardiovascular Imaging* (2012) 13, 69–78.
4. Ramil Goel, MD, et al. Coronary Artery Calcification and Coronary Atherosclerotic Disease. *Cardiol Clin* 30 (2012) 19–47
5. Richard T. George, MD, et al. Myocardial Perfusion by CT versus Hybrid Imaging. *Cardiol Clin* 30 (2012) 135–146